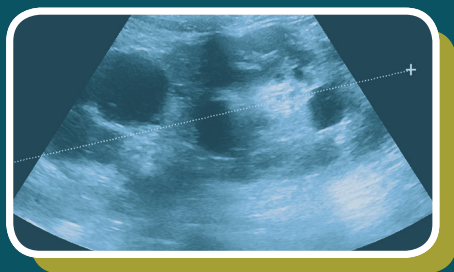
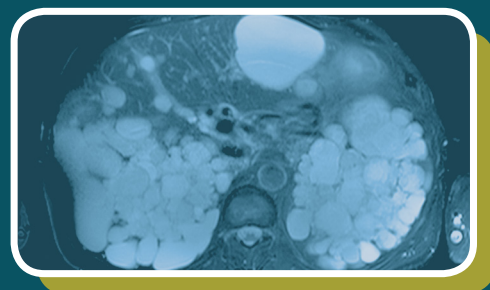
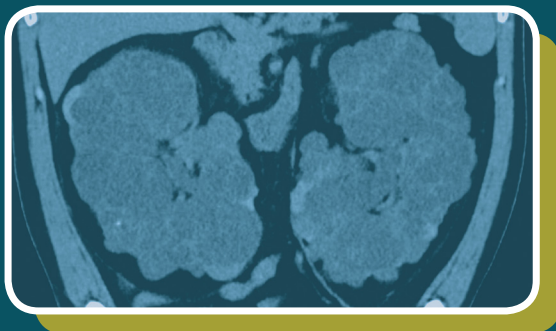


IMAGING THE KIDNEYS IN ADPKD

How imaging results can help assess
disease progression

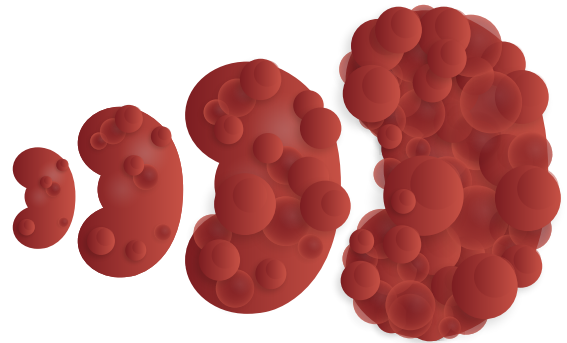


ADPKD=autosomal dominant polycystic kidney disease.

Autosomal dominant polycystic kidney disease (ADPKD) is a progressive and inherited kidney disease¹

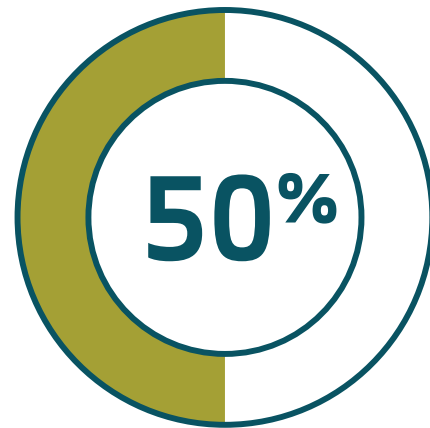
- ADPKD is a genetic disease characterized primarily by the development and progressive enlargement of fluid-filled renal cysts^{1,2}

Over time, enlarging cysts cause an increase in total kidney volume (TKV) up to 4 times that of normal kidneys³



- This contributes to compression and loss of the surrounding functional renal tissue, resulting in a progressive decline of renal function^{1,4}

Nearly 50% of all patients with ADPKD will reach end-stage renal disease by age 60⁵



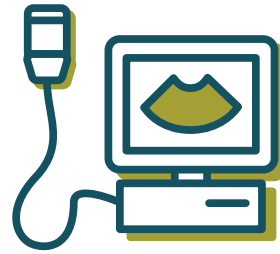
Each child of a person with ADPKD has a 50% chance of inheriting the abnormal gene²

Multiple techniques can be used to confirm a diagnosis of ADPKD⁶

Diagnosis of ADPKD is typically established on the basis of⁶:



Positive Family History




Imaging Studies


When there is no clear family history or when results from imaging studies are not consistent with ADPKD, genetic testing is available to help confirm a diagnosis.⁶

Ultrasound is the most commonly used imaging modality for diagnosis of ADPKD⁷


Unified ultrasonographic criteria for diagnosis of ADPKD in patients with positive family history (Pei criteria)⁸:



Criteria
15-39 YEARS
At least 3 renal cysts
(unilateral or bilateral)



Criteria
40-59 YEARS
At least 2 cysts in
each kidney



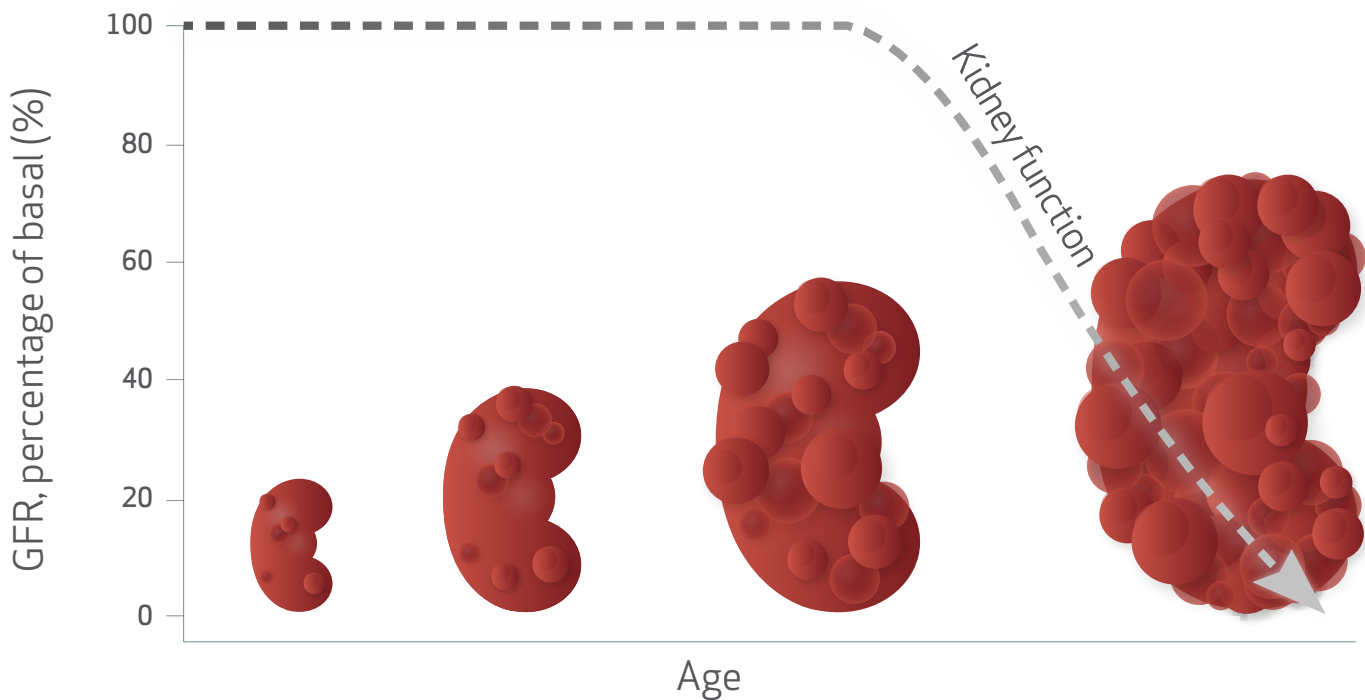
Criteria
≥60 YEARS
At least 4 cysts in
each kidney

Criteria based on age and cyst count in patients with a positive family history.

Disease course in ADPKD

The rate at which ADPKD advances can be variable, and patients may remain asymptomatic for years.⁴

Cyst growth precedes decline in kidney function^{4,9}



Adapted from Grantham JJ, et al. *Nat Rev Nephrol.* 2011;7(10):556-566.

- During this time, the kidneys continue to increase in volume and damage continues to progress¹⁰
- For patients with rapidly progressing ADPKD, this can result in a significant cystic burden at a young age⁶

Imaging and clinical markers, as well as family history, can be used to predict the rate of disease progression in ADPKD¹¹

TKV can help predict disease progression in ADPKD¹²

Predictors of rapid disease progression

Identifying a TKV greater than expected for age can provide an early and reliable marker for rapid disease progression in ADPKD¹³

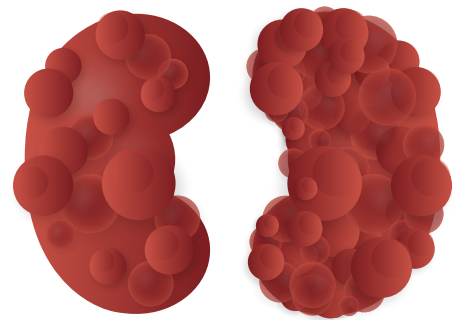
Additional clinical predictors of rapid disease progression include an estimated glomerular filtration rate (eGFR) decline ≥ 5 mL/min/1.73 m² in one year, onset of hypertension before age 35, and urologic events such as hematuria, flank pain, or cyst infection before age 35.¹¹

Even before eGFR levels begin to drop, TKV can provide an important predictor of^{14,15}:

- Early-stage disease progression
- Future renal decline

In 2016, the FDA provided a recommendation for the use of TKV, measured at baseline, as a prognostic enrichment biomarker for clinical trials to select patients with ADPKD at high risk of a progressive decline in renal function.¹⁶

A baseline height-adjusted total kidney volume (htTKV) >600 mL/m predicted the development of CKD stage 3 within 8 years in the CRISP* cohort¹²



eGFR should continue to be used concomitantly with TKV to monitor renal function in your patients with ADPKD⁵

*Consortium for Radiologic Imaging Studies in Polycystic Kidney Disease.
CKD=chronic kidney disease.

TKV measurement techniques

TKV can be measured using magnetic resonance imaging (MRI), computed tomography (CT), and ultrasonography.¹⁷

Manual planimetry and the ellipsoid formula are 2 of the recommended techniques available for measuring TKV.¹⁷

Volume analysis ¹⁷	Manual planimetry	Ellipsoid formula
Imaging modality	MRI and CT scan*	MRI, CT scan,* and ultrasound
Analysis time	40 minutes	5 minutes
Accuracy	100% [†]	87% (MRI, CT), 21% ultrasound [†]
Directions	<ul style="list-style-type: none"> • Trace kidney outline onto cross-sectional images • Multiply all traced areas by slice thickness • Combine slice volumes 	<ul style="list-style-type: none"> • Measure length, width, and depth for both left and right kidneys • Calculate volume with ellipsoid formula <p>-See page 8 for more information about the ellipsoid formula</p>

*CT-related data were not available, but by approximation can be considered close to MRI methodology.¹⁷

[†]Measurement accuracy according to Mayo Clinic model classification.

ADPKD imaging modalities

There are advantages and drawbacks to each of the imaging modalities for measuring kidney and cyst volumes.¹⁷

Imaging modality ¹⁷	Abdominal MRI	Abdominal CT	Ultrasound
Measurement accuracy	Can detect cysts ≥ 2 mm in diameter	Can detect cysts ≥ 2 mm in diameter	Can detect cysts >1 cm in diameter
Advantages	<ul style="list-style-type: none"> • Can reliably measure kidney volume over short periods of time with minimal bias and low inter- and intraoperator variability • Allows segmentation of individual cysts providing quantitative assessment of disease 	<ul style="list-style-type: none"> • Provides accurate and reliable measurement of TKV and cyst volume in ADPKD 	<ul style="list-style-type: none"> • Does not require radiation • Widely available • Low cost
Drawbacks	<ul style="list-style-type: none"> • Cost • Lack of availability 	<ul style="list-style-type: none"> • Potentially nephrotoxic contrast medium • Exposure to radiation 	<ul style="list-style-type: none"> • Lacks precision and accuracy for detecting short-term changes in kidney volume • Highly operator-dependent

Ordering a TKV measurement

A single baseline htTKV measurement can help predict disease progression.¹⁸

Steps for ordering a TKV measurement

1 Determine diagnosis of ADPKD

Age ____

Number of cysts: Right kidney ____ Left kidney ____

Family history of ADPKD: Yes ____ No ____

2 Perform abdominal/limited abdominal CT or MRI* scans, or ultrasound¹⁷

Choose a volume analysis technique:

Manual planimetry: Request TKV from radiologist

or

Ellipsoid formula: Request length, width, and depth dimensions (mm) for the right and left kidneys

- Review image to determine typical[†] or atypical[‡] PKD
- If typical, calculate TKV

LEFT KIDNEY	+	RIGHT KIDNEY	=	TKV
$\frac{\pi}{6} \times (L \times W \times D)$		$\frac{\pi}{6} \times (L \times W \times D)$		

L=length; W=width; D=depth.

Units for kidney dimensions are in mm. To get kidney volume in mL, multiply by 0.001.

3 Calculate htTKV¹²

$$\frac{TKV}{h} = htTKV$$

TKV in mL and height in m for a htTKV in mL/m.

*MRI without gadolinium.

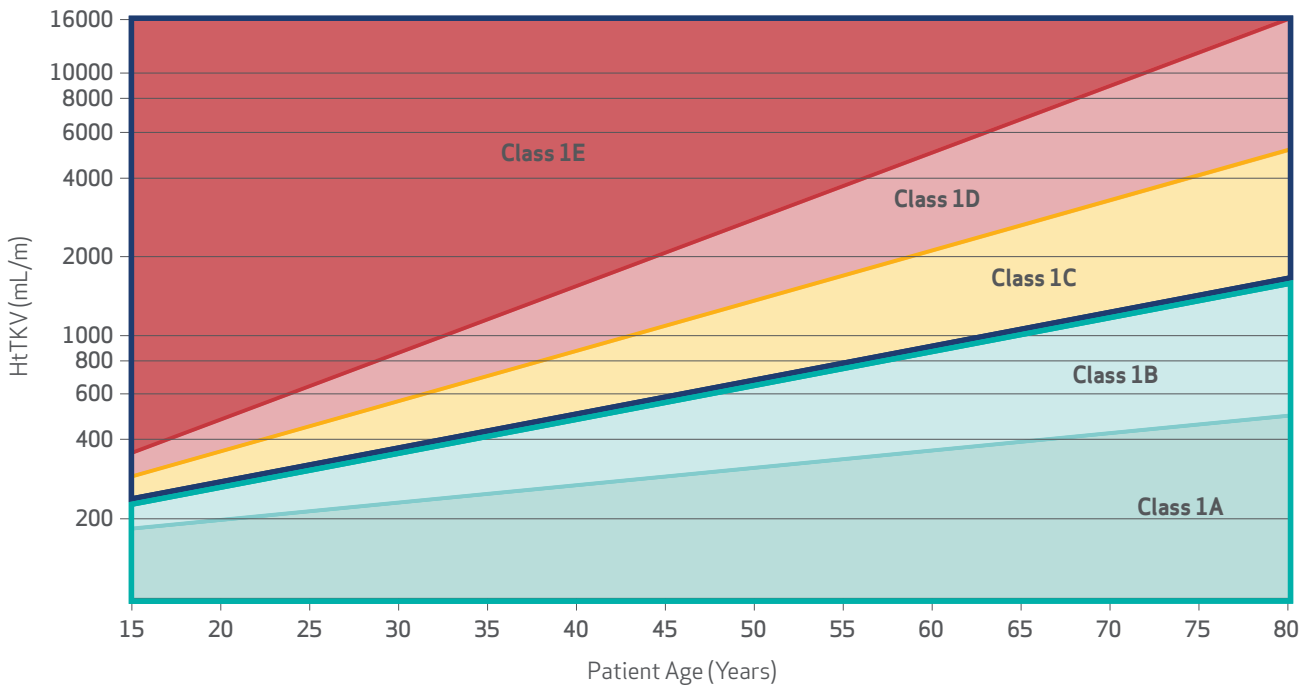
[†]Bilateral and diffuse distribution, with mild, moderate, or severe replacement of kidney tissue by cysts, where all cysts contribute similarly to TKV.¹⁷

[‡]Unilateral, segmental, asymmetric, or lopsided presentation, or a bilateral presentation with acquired unilateral atrophy or bilateral kidney atrophy.¹⁷
PKD=polycystic kidney disease.

Assessing disease progression from htTKV

HtTKV acquired by MRI or CT can be used to determine a patient's ADPKD imaging classification and help identify adult patients at a high risk of rapid disease progression.¹⁹

ADPKD imaging classification by htTKV and age predicts the change in eGFR over time in patients with typical ADPKD^{19*}



*Bilateral and diffuse distribution, with mild, moderate, or severe replacement of kidney tissue by cysts, where all cysts contribute similarly to TKV.¹⁹

Republished with permission of the American Society of Nephrology, from Imaging classification of autosomal polycystic kidney disease: a simple model for selecting patients for clinical trials. *J Am Soc Nephrol.* 2015;26(1):160-172.

Patient classification ^{19†}					
Class	1A	1B	1C	1D	1E
Estimated kidney growth rate: yearly percentage increase	<1.5%	1.5%-3%	3%-4.5%	4.5%-6%	>6%
Risk for eGFR decline	Low risk	Intermediate risk	High risk	High risk	High risk

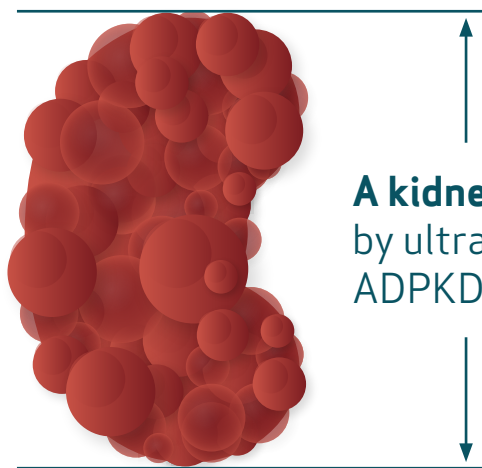
†Classification only applies to patients with typical morphology of ADPKD as defined by diffuse bilateral cystic involvement of the kidneys.¹⁹

~2/3

of the ADPKD patients evaluated in the ADPKD imaging classification study were identified to be at risk of rapid progression¹⁹

Ultrasound kidney length can be used when MRI isn't available²⁰

Ultrasound-derived kidney length has been proposed as a surrogate for MRI-measured TKV for predicting disease progression.²⁰



A kidney length of >16.5 cm bilaterally measured by ultrasound is an indicator of rapidly progressing ADPKD in patients <45 years of age^{11,20*}

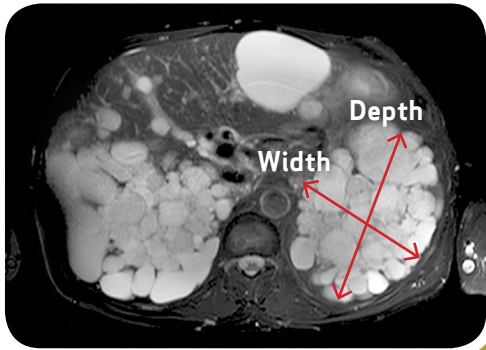
In the CRISP study, ADPKD patients <45 years of age with CKD stage 1 or 2,[†] a kidney length >16.5 cm has been shown to predict the future development of CKD stage 3a within 8 years.^{11,20}

*A direct measurement of TKV would be required if more accurate assessment is needed.

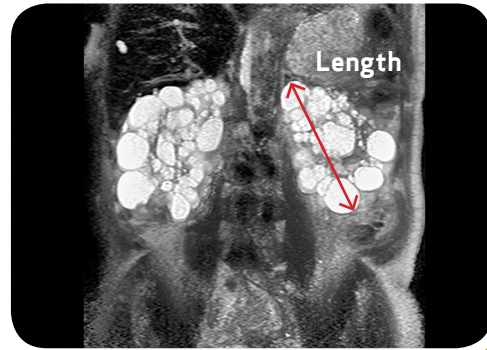
[†]Average baseline eGFR of 98 mL/min/1.73m².

Imaging examples

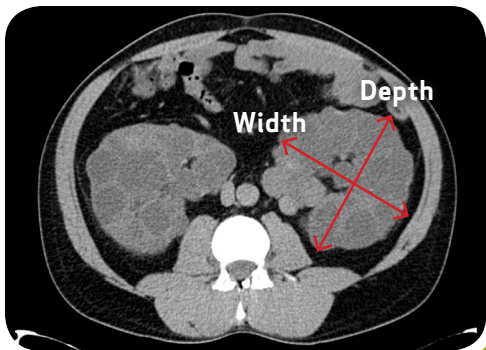
Visualizing ADPKD using MRI, CT, and ultrasonography



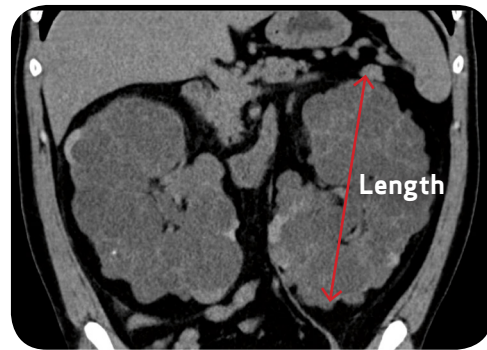MRI: Axial slice, typical ADPKD presentation with bilateral, diffuse distribution of cysts



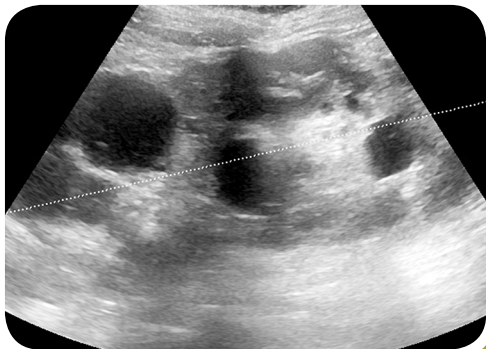
MRI: Coronal slice, typical ADPKD presentation with bilateral, diffuse distribution of cysts



CT image: Axial slice, typical ADPKD presentation with bilateral, diffuse distribution of cysts



CT image: Coronal slice, typical ADPKD presentation with bilateral, diffuse distribution of cysts



Ultrasound scan: Left kidney in typical ADPKD presentation with diffuse distribution of cysts

Image your patients' kidneys to help predict their risk of disease progression in ADPKD

References: **1.** Patel V, Chowdhury R, Igarashi P. *Curr Opin Nephrol Hypertens*. 2009;18(2):99-106. doi:10.1097/MNH.0b013e3283262ab0 **2.** Torres VE, Grantham JJ. In: Taal MW, Chertow GM, Mardsen PA, Skorecki K, Yu ASL, Brenner BM, eds. *Brenner & Rector's The Kidney*. Philadelphia, PA: Elsevier Saunders; 2012:1626-1667. **3.** Braun WE. *Cleve Clin J Med*. 2009;76(2):97-104. **4.** Grantham JJ, Mulamalla S, Swenson-Fields KI. *Nat Rev Nephrol*. 2011;7(10):556-566. **5.** Chebib FT, Torres VE. *Am J Kidney Dis*. 2016;67(5):792-810. doi:10.1053/j.ajkd.2015.07.037 **6.** Chebib FT, Perrone RD, Chapman AB, et al. *J Am Soc Nephrol*. 2018;29(10):2458-2470. doi:10.1681/ASN.2018060590 **7.** Pei YH, Hwang Y, Conklin J, et al. *J Am Soc Nephrol*. 2015;26(3):746-753. doi:10.1681/ASN.2014030297 **8.** Pei Y, Obaji J, Dupuis A, et al. *J Am Soc Nephrol*. 2009;20(1):205-212. doi:10.1681/ASN.2008050507 **9.** Grantham JJ, Chapman AB, Torres VE. *Clin J Am Soc Nephrol*. 2006;1(1):148-157. **10.** Chapman AB, Guay-Woodford LM, Grantham JJ, et al. *Kidney Int*. 2003;64(3):1035-1945. **11.** Gansevoort RT, Arici M, Benzing T, et al. *Nephrol Dial Transplant*. 2016;31(3):337-348. **12.** Chapman AB, Bost JE, Torres VE, et al. *Clin J Am Soc Nephrol*. 2012;7(3):479-486. **13.** Helal I, Reed B, Schrier RW. *Am J Nephrol*. 2012;36(2):162-167. **14.** Grantham JJ, Torres VE. *Nat Rev Nephrol*. 2016;12(11):667-677. **15.** Perrone RD, Neville J, Chapman AB, et al. *Am J Kidney Dis*. 2015;66(4):583-590. doi:10.1053/j.ajkd.2015.04.044 **16.** Qualification of biomarker total kidney volume in studies for treatment of autosomal dominant polycystic kidney disease. US Food and Drug Administration website. <https://www.fda.gov/downloads/Drugs/Guidances/UCM458483.pdf>. Accessed December 13, 2018. **17.** Magistroni R, Corsi C, Martí T, Torra R. *Am J Nephrol*. 2018;48:67-78. doi:10.1159/000491022 **18.** Yu ASL, Shen C, Landsittel DP, et al; for the Consortium for Radiologic Imaging Studies of Polycystic Kidney Disease (CRISP). *Kidney Int*. 2018;93(3):691-699. **19.** Irazabal MV, Rangel LJ, Bergstralh EJ, et al. *J Am Soc Nephrol*. 2015;26(1):160-172. **20.** Bhutani H, Smith V, Rahbari-Oskoui F, et al; for the CRISP Investigators. *Kidney Int*. 2015;88(1):146-151. doi:10.1038/ki.2015.71